

Ref – Bhutada T, Dash BK, Sarita Otta S. Suicidal poisoning by Acetic acid: Two autopsy reports from Eastern India. *Anil Aggrawal's Internet Journal of Forensic Medicine and Toxicology* [serial online], 2024; Vol. 25, No. 2 (July - December 2024): [about 22 p]. Available from: [http://anilaggrawal.com/ij/vol\\_025\\_no\\_002/papers/paper001.html](http://anilaggrawal.com/ij/vol_025_no_002/papers/paper001.html). Published as Epub Ahead: Feb 11, 2024.

Access the journal at - <http://anilaggrawal.com>

DOI : [10.5281/zenodo.10646676](https://doi.org/10.5281/zenodo.10646676)

# Suicidal poisoning by Acetic acid: Two autopsy reports from Eastern India

**1-Tushar Bhutada**, (FMT), Assistant Professor, KIMS Medical College and Hospital

**2- Braja Kishore Dash**, MD (FMT), Additional DMET, Odisha

**3- Sarita Otta \***, MD (Microbiology), Associate professor, IMS and SUM Hospital

**Name(s) of department(s) and/ or institution(s)**

Department of FMT, KIMS Medical College and Hospital, Patia, Bhubaneswar

**Corresponding author-**

\*Dr Sarita Otta

Dept of Microbiology, IMS and SUM Hospital, Kalinga Nagar, Bhubaneswar, 751003,

Ph- 9438529628, Email-saritaotta@gmail.com

## **Abstract**

**Background-**Acetic acid is a common corrosive acid available as a household product and is used in several industries, including rubber, food, and leather goods. Its use as vinegar (5-10 % acetic acid), a tabletop condiment, is common. However, its use in suicides is limited because of its pungent smell and taste. It is thus rare to encounter such cases by the forensic pathologists and

clinicians. We here present two cases of suicidal poisonings by vinegar in a setting made convenient by their easy accessibility. The present case also highlights that the unregulated cheese curd (chenna) industry workers are the likely candidates for such cases.

**Case presentation-** We present two cases where the deceased was brought forward for the autopsy examination following a verbal declaration by the near and dear of vinegar intake. Both cases were working in the food industry to prepare curd cheese. The cases had erosions in the stomach with reflex pylorospasm. The first case succumbed to multi organ failure resulting from systemic toxicity of the acid, while the second case died before receiving any medical attention because of asphyxia resulting from laryngeal edema. **Conclusion-** The amount of the ingested corrosive and grading of the mucosal necrosis determines the prognosis of the acetic acid ingestion. The present case report suggests that appropriate policy needs to be made for the preservation and accountability of these chemicals in industrial settings to prevent such mishaps in the future.

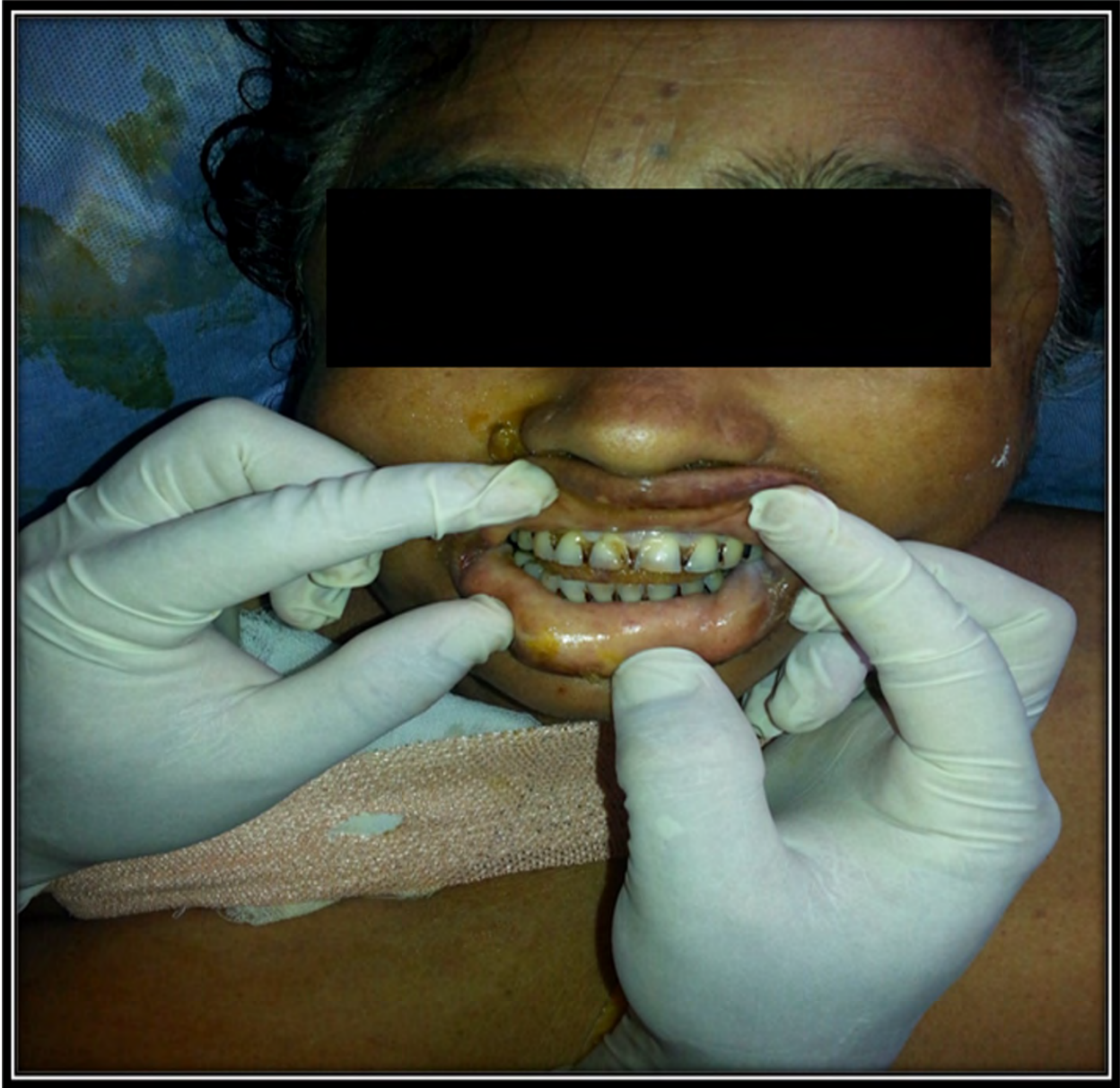**Keywords - Acetic acid poisoning, Vinegar poisoning, Zargar grading, Case report, Suicide**

**Background-** Corrosives act as contact poisons as they corrode and destroy the tissues they come in contact with, besides manifesting various systemic complications after their absorption into the blood. While reports from America<sup>1</sup> and Europe<sup>2</sup> suggest alkalis as the most common corrosive substance ingested, studies from India report acids to be the most commonly ingested corrosives.<sup>3</sup> Common corrosive acids like sulphuric acid, hydrochloric acid, and nitric acid are implicated in suicidal poisonings. Owing to the easy availability of vinegar (5% acetic acid) in households, accidental poisoning is not uncommon, considering its similarity with other clear liquids. However, the pungent odor and repugnant taste serve to limit its accidental poisonings beyond one or two sips, causing milder injuries. However, people with suicidal intentions who deliberately

drink large amounts of vinegar often land on the fatal end of the spectrum.<sup>4</sup> The present study reports two cases of suicidal poisoning and deaths following deliberate self-ingestion of vinegar. The family profession in both these cases was to commercially prepare cheese curd ('Chenna'), which requires treating milk with vinegar, thus making the chemical easily assessable to the deceased. The present case series aims to throw light on a rarely seen use of a typical household condiment in large quantities to aid in suicide.

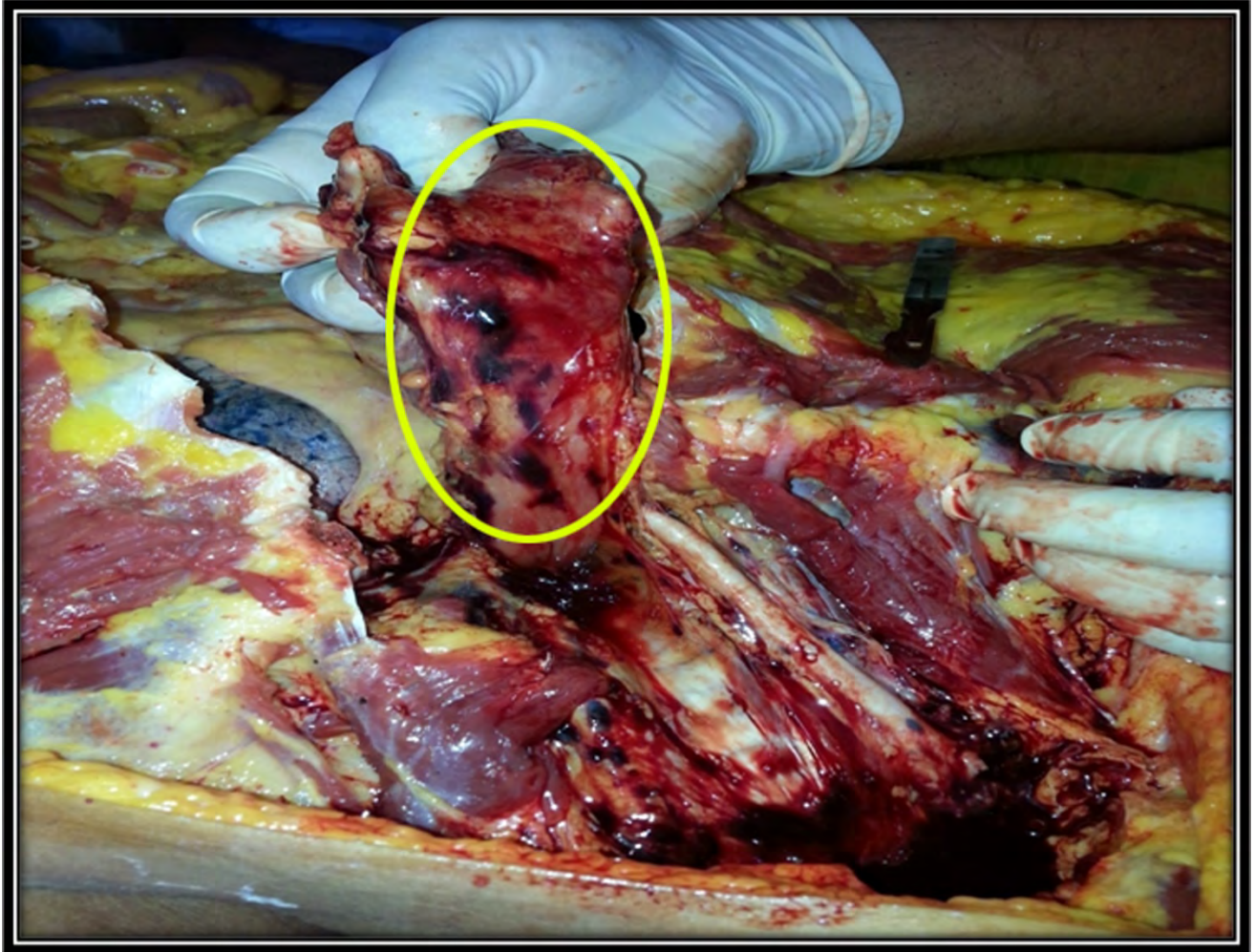
### **Case Presentation**

**Case 1-** Average built 66-year-old female deceased, measuring 144 cm in length and 54 kg in weight, presented to the autopsy room after inpatient death following 72 hours of hospital stay. The patient was being treated for complications arising from ingestion of vinegar, which she had allegedly consumed deliberately following a familial altercation with her son. External examination revealed no injury except excoriation and yellowish discoloration in the middle of the lower lip. **[Figure-1]**

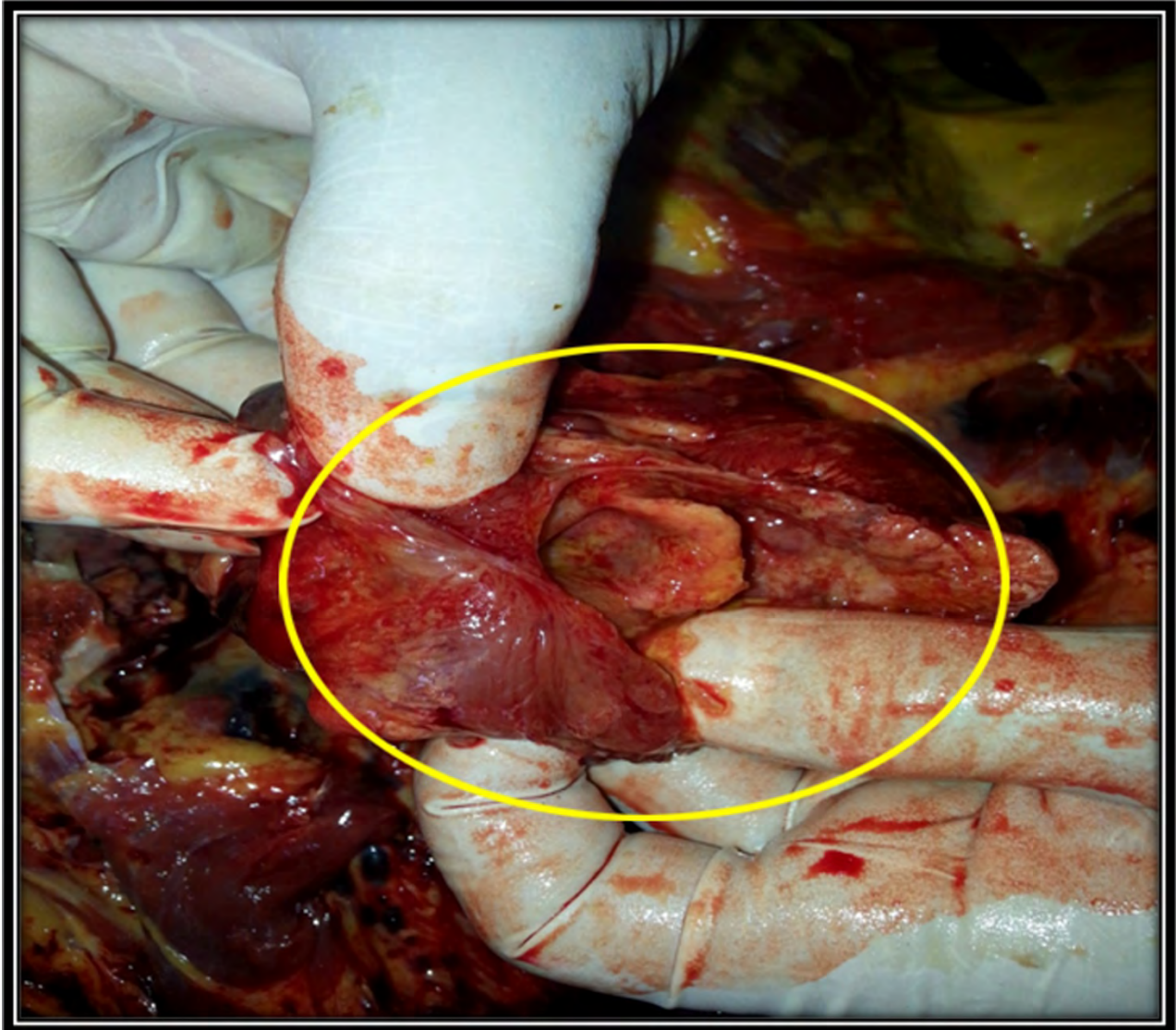


*Figure 1 - Discoloration and excoriation of lips in Case 1.*

In the oral cavity, there was chalky white discoloration of the teeth. Yellowish discoloration of the epiglottis, **[Figure-2, 3]** lower pharynx and yellowish mucosal excoriation in the lumen of larynx were also noted.

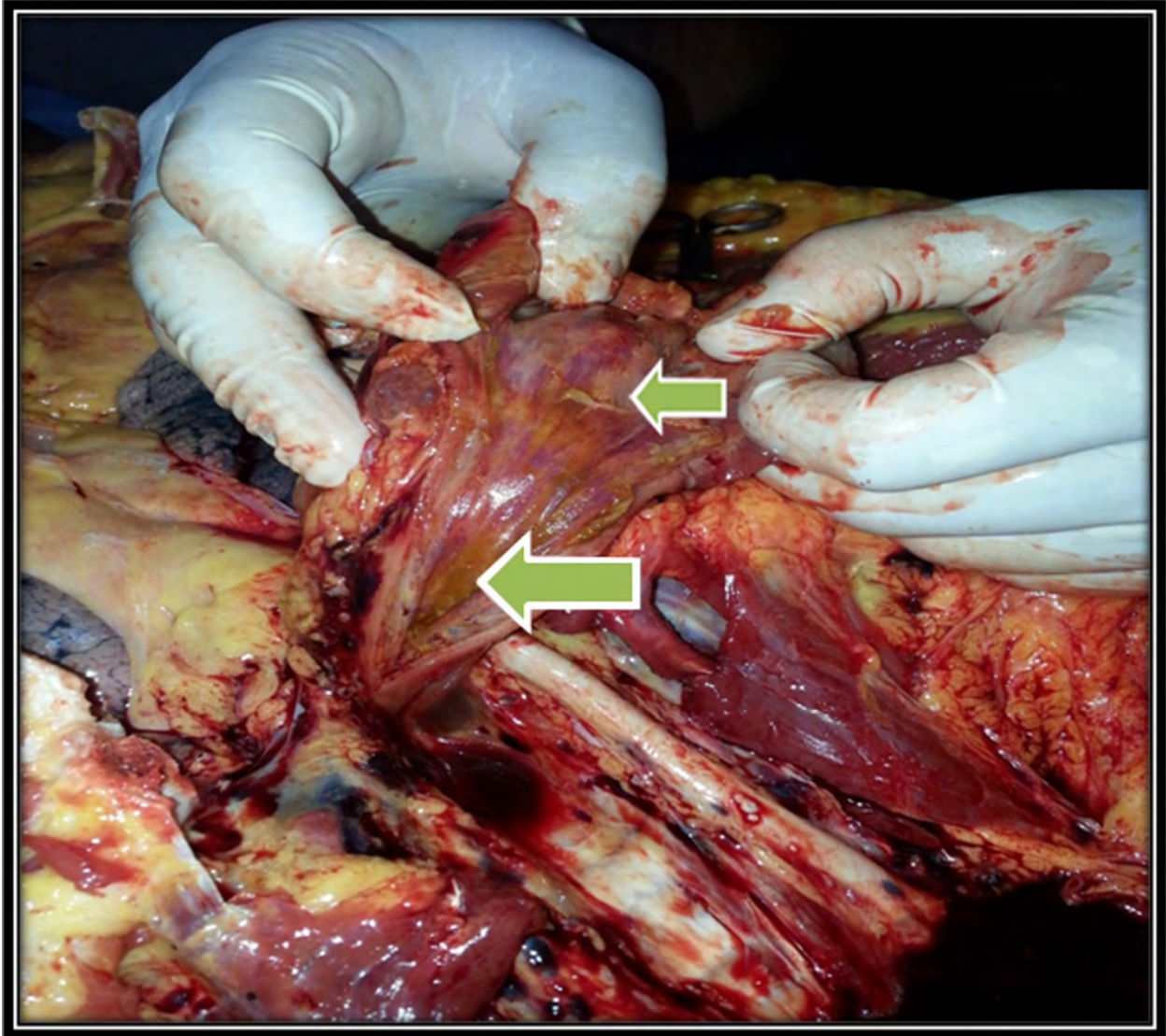


*Figure 2 - Congestion seen around the epiglottis in Case 1.*



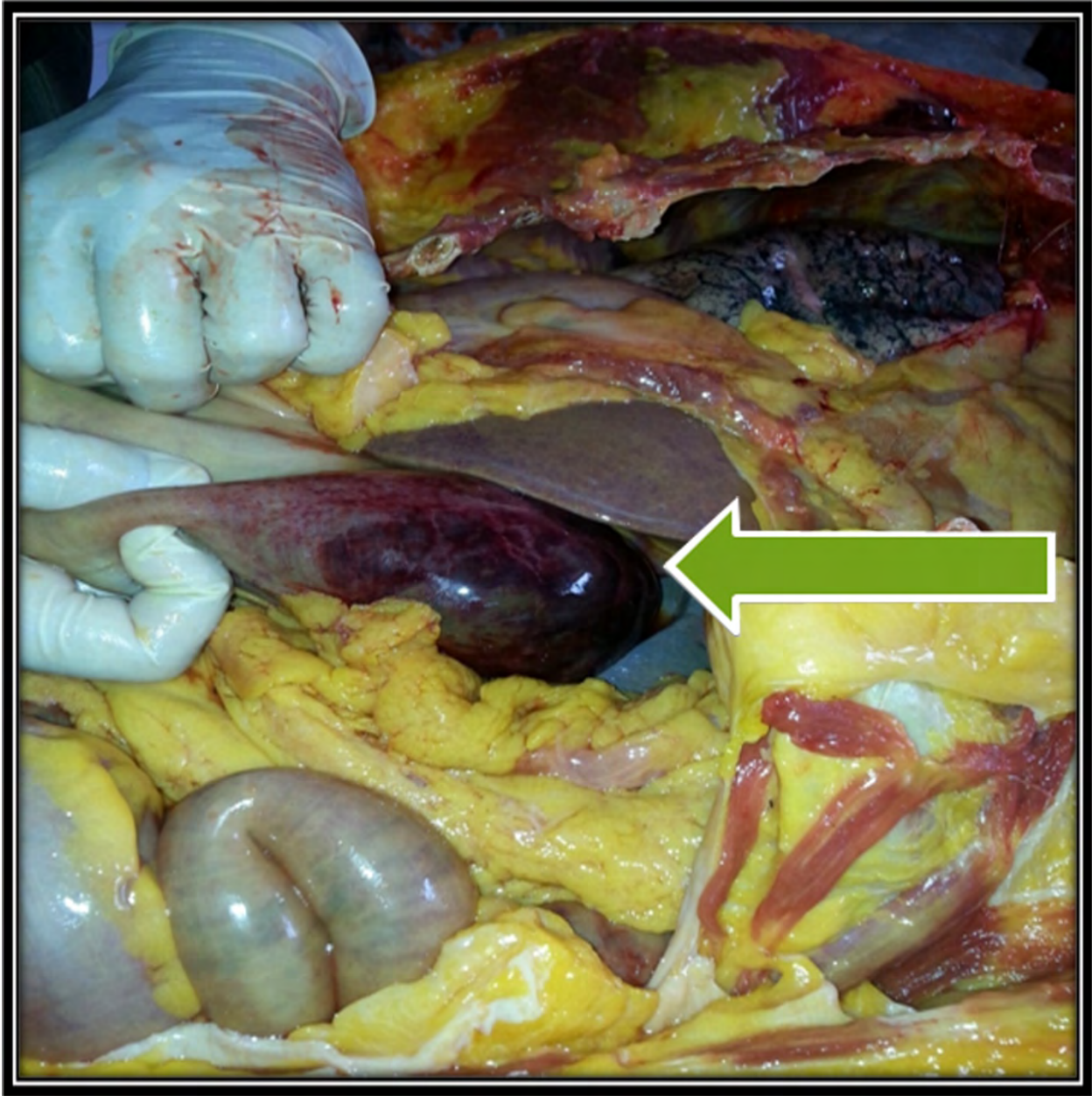
*Figure 3 - Yellowish discoloration with excoriation on the internal wall of esophagus in case 1.*

Congestion was noted around the posterior aspect of the esophagus was evident. **[Figure- 4].**

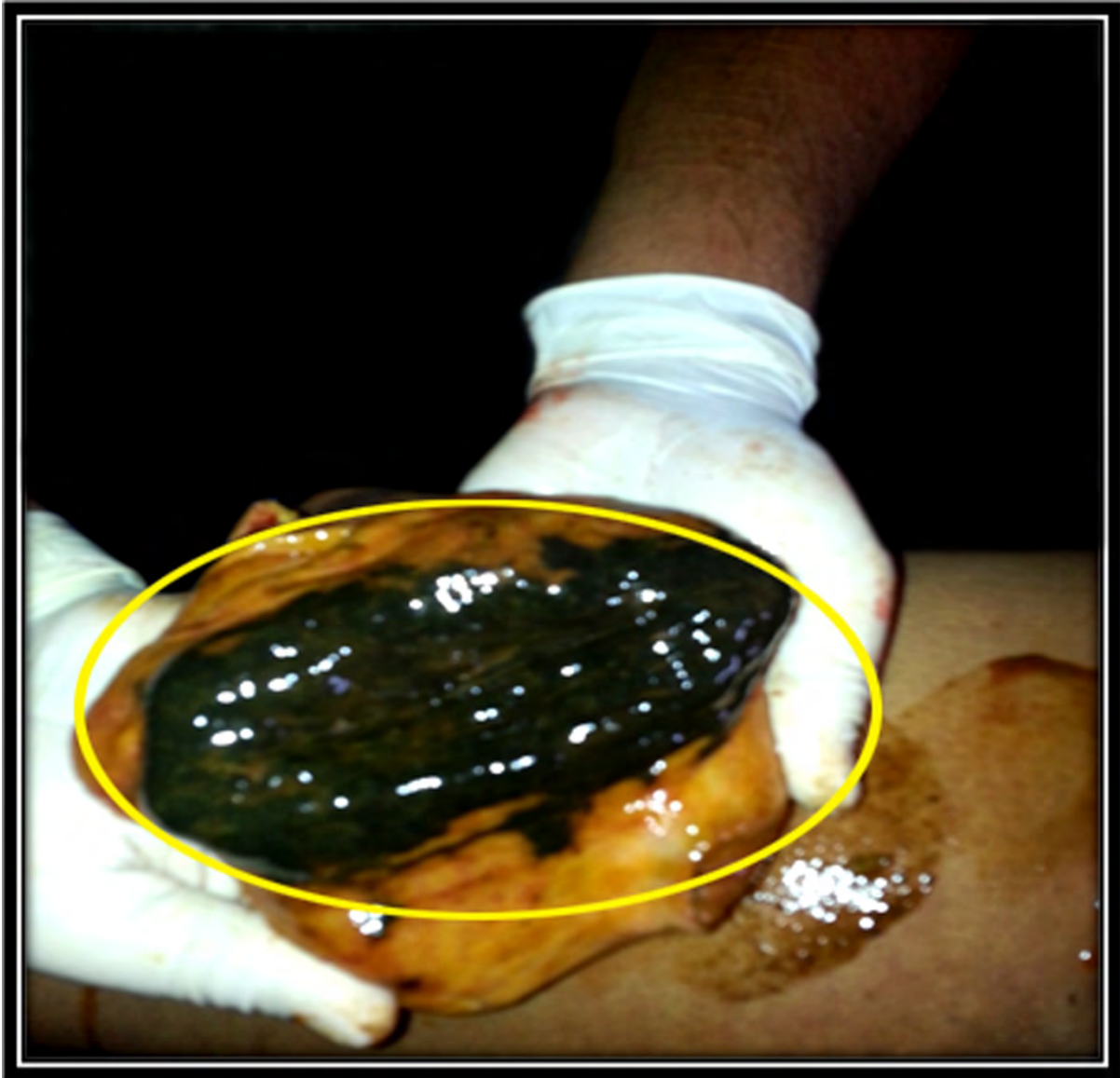

*Figure 4 - Congestion seen around the posterior aspect of the esophagus in case 1.*

The gastric content weighed approximately 25 ml and was a greenish-yellow liquid with no suspicious odor. The stomach mucosa had diffuse pinpoint hemorrhages in the proximal end. The entire thickness of the gastric wall in the distal end of the stomach was turned into a black spongy mass probably because of pylorospasm [Figure-5, 6] and the resultant pooling of the corrosive liquid at the distal end.

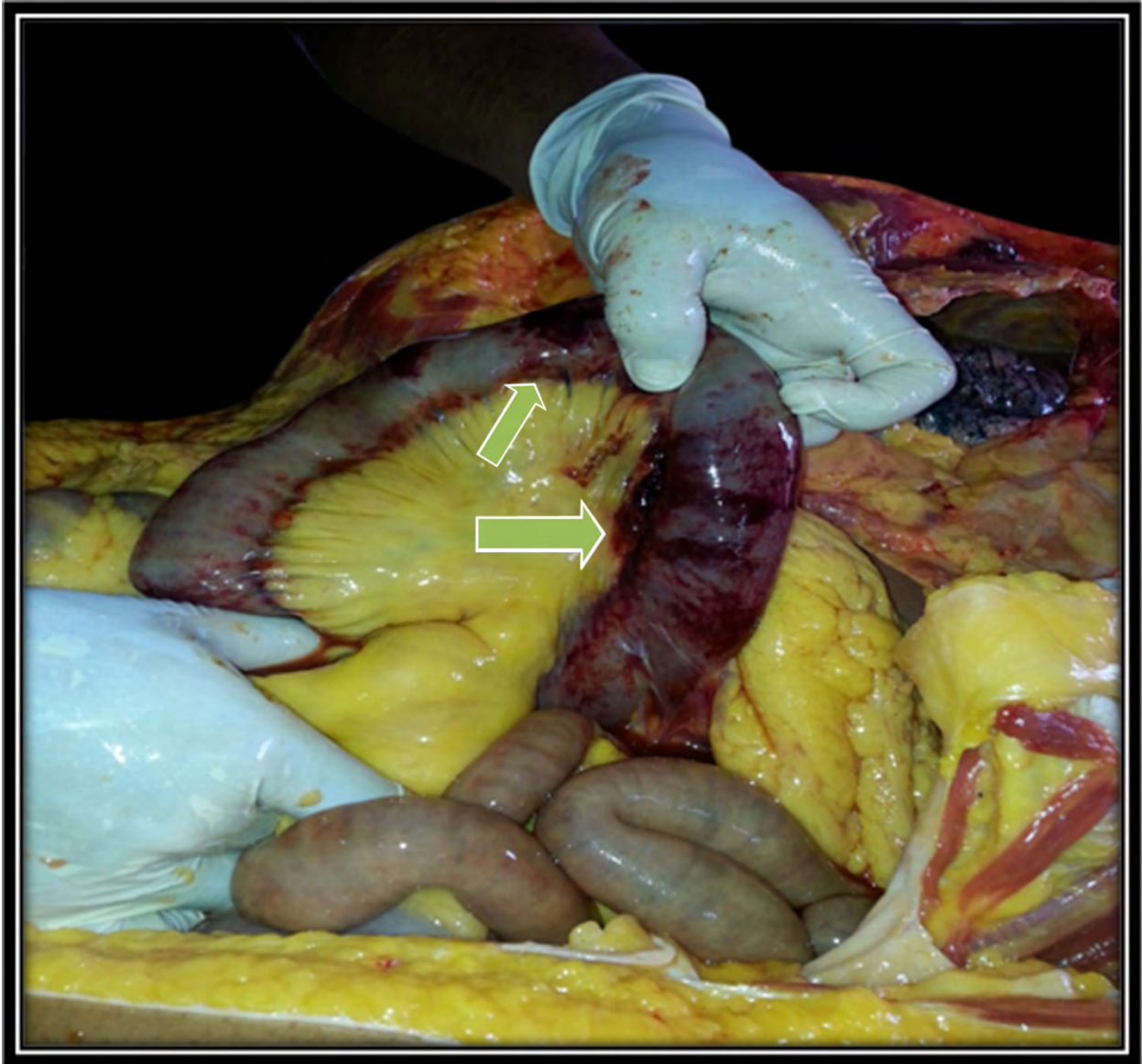


*Figure 5 - Congestion seen on the outside wall of stomach in case 1.*



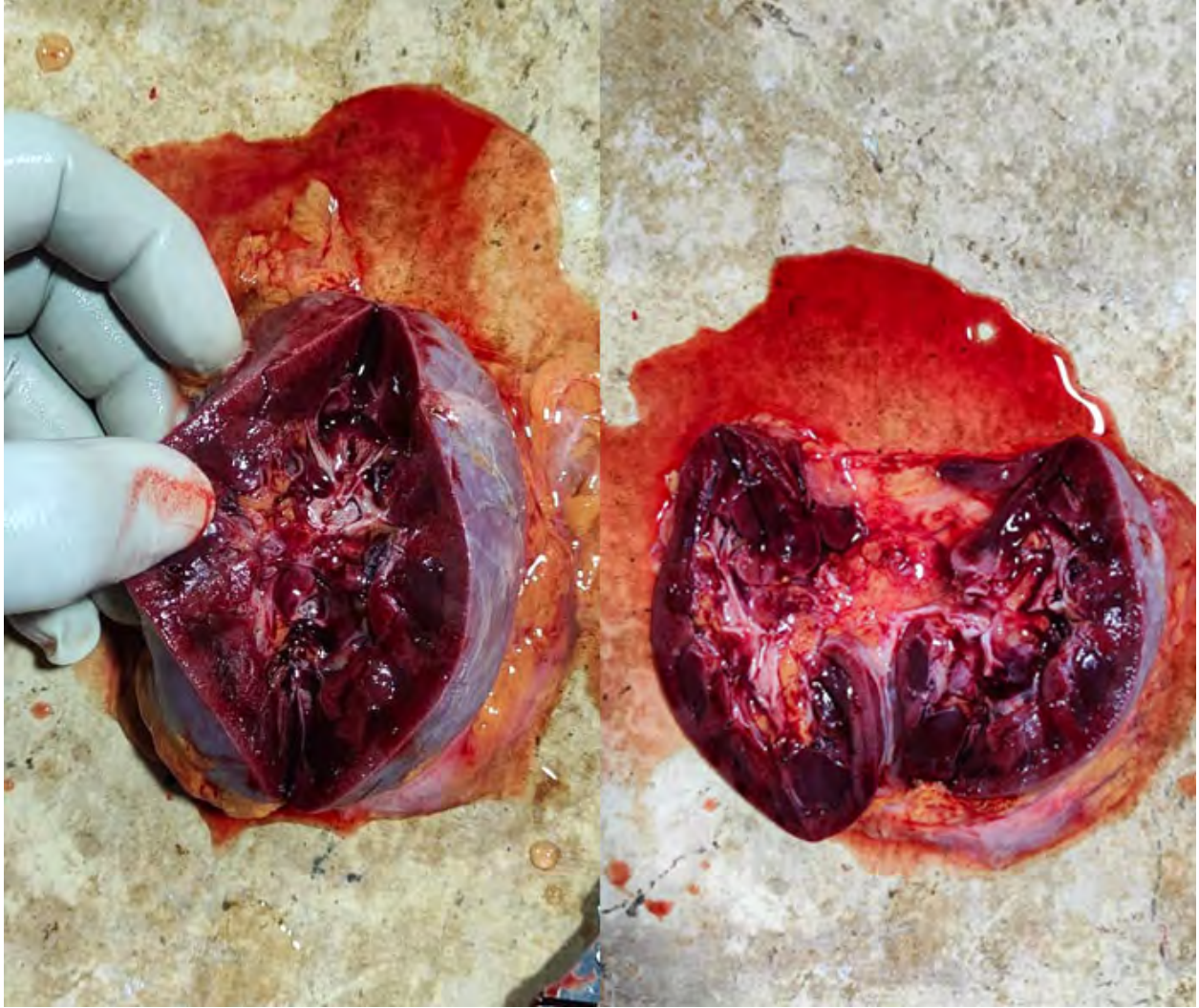
*Figure 6 - Pyloric end of the stomach showing circumferential and full thickness blackish discoloration in case 1.*

Hyperemia of the small bowel could be appreciated from the serosal surface [**Figure- 7**].



*Figure 7 - Congestion seen in the outside wall of small intestine in case 1.*

The large bowel appeared healthy and contained fecal matter. Both the kidneys appeared congested. [Figure-8].

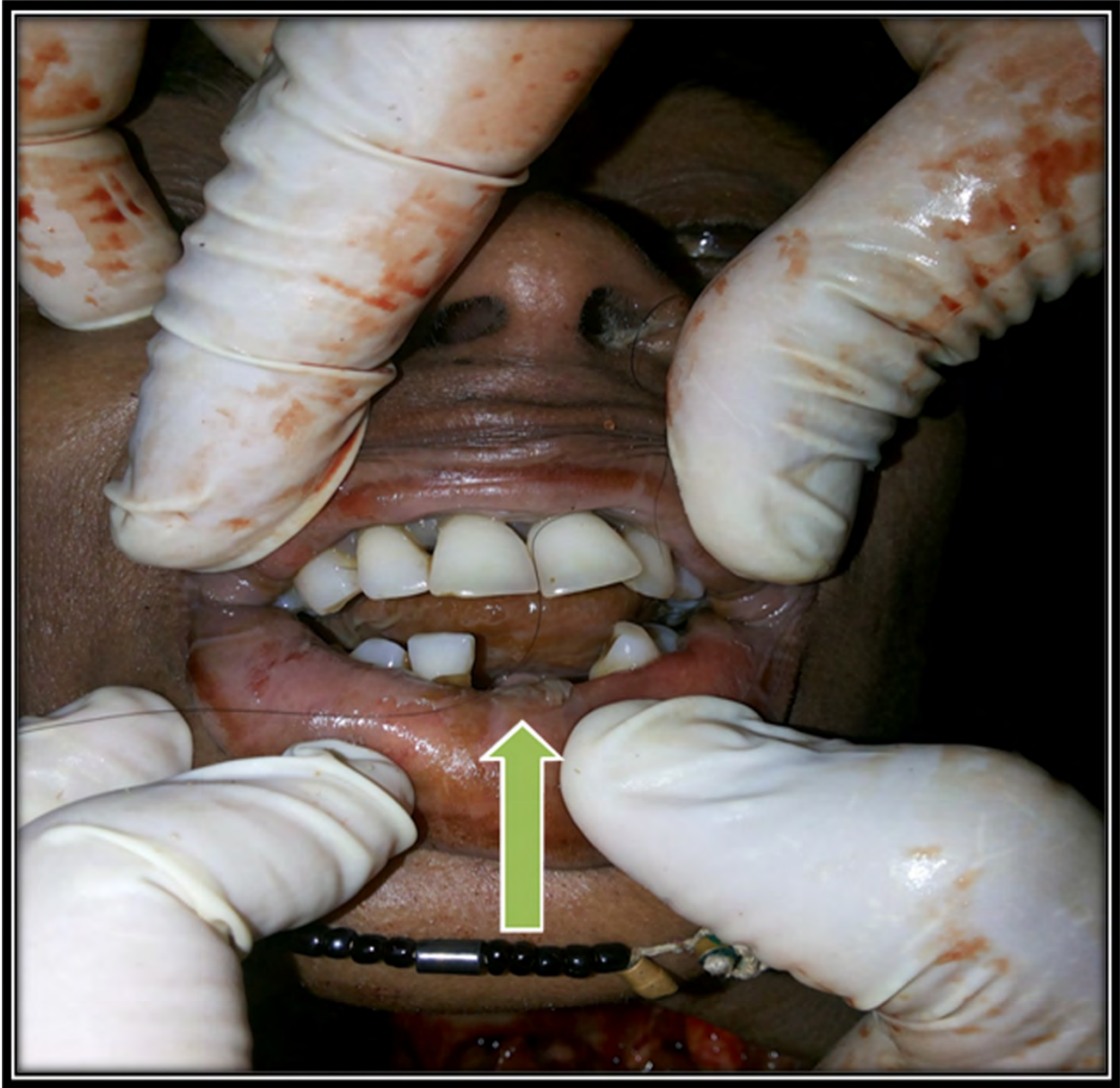


*Figure 8 - Longitudinal section showing congestion on the left kidney in case 1.*

In the histopathology study, there was cellular coagulation necrosis of the esophagus and lining mucosa of stomach. Post-mortem toxicology analysis of the viscera and the blood from the subclavian vein confirmed the presence of benzodiazepine besides confirming acetic acid. Unfortunately, as is the routine practice in this part of the world, quantitative estimate of the acetic acid or benzodiazepine found in the viscera was not done.

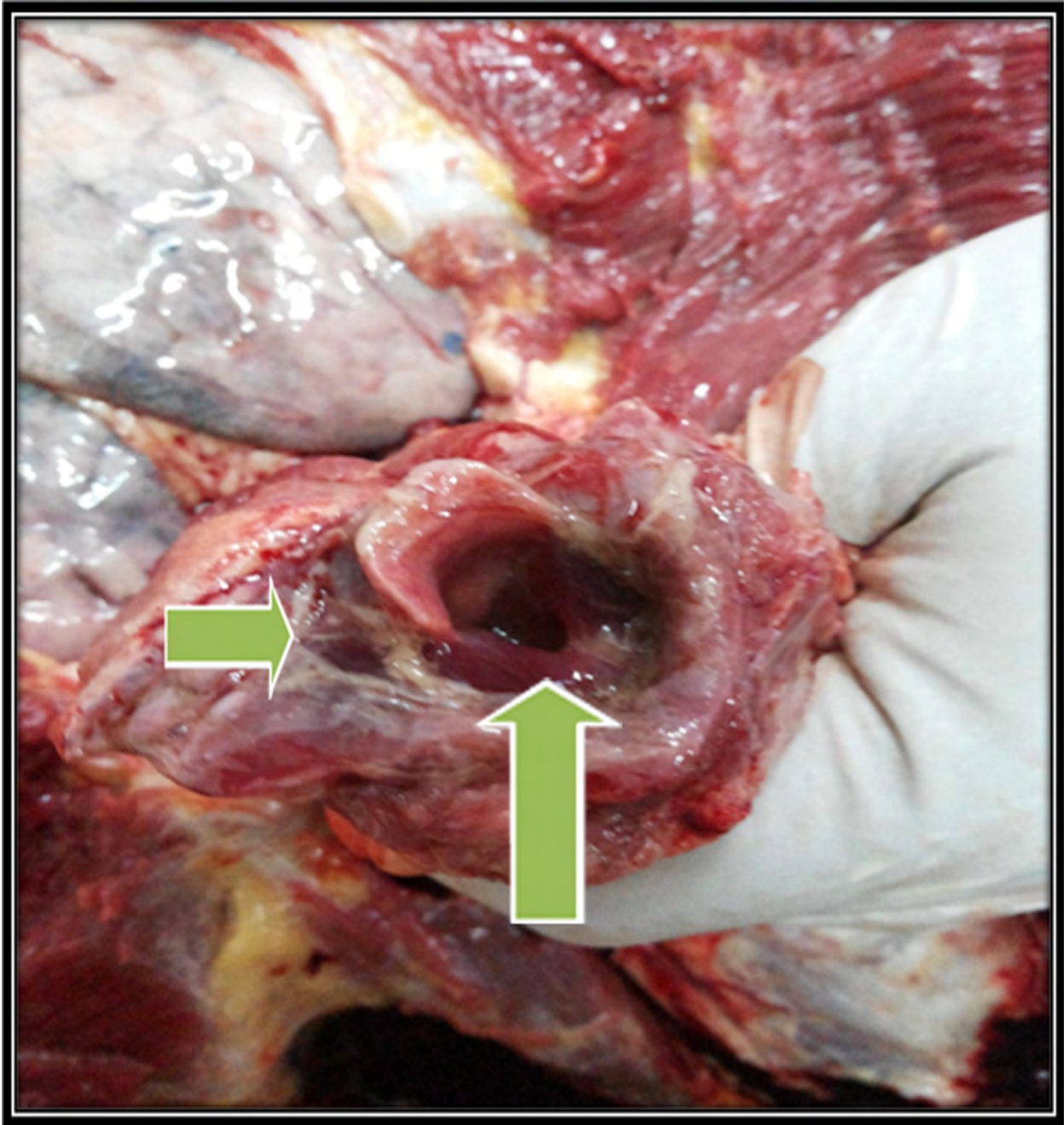
On verbal autopsy, the family member confirmed that the deceased was habitually taking alprazolam for insomnia. The patient was admitted to a tertiary care hospital for the last 72 hours and had received gastric lavage. Benzodiazepine poisoning was not considered in the working diagnosis by the attending physician as well as police after not having any corroborative evidence like missing/ empty foils of tablets in the patient's home. Moreover, her son provided a history of supervised intake of sleeping pills. She succumbed during treatment due to multi-organ failure and shock. Mechanisms of death may have been acidemia, hematuria, renal failure, hepatic failure, and shock. The manner of the death was suicide. The cause of death was given as multi organ failure due to vinegar ingestion and its metabolic complications.

**Case 2-** A 46-year-old thin built female deceased, weighing 48 kg and height 150 cm, was brought to the mortuary directly by the police following death at her home. External examination of the body did not reveal any injury. In the oral cavity, the anterior teeth appeared chalky white; the tongue was edematous sodden with anterior yellowish discoloration. **[Figure-9]**.



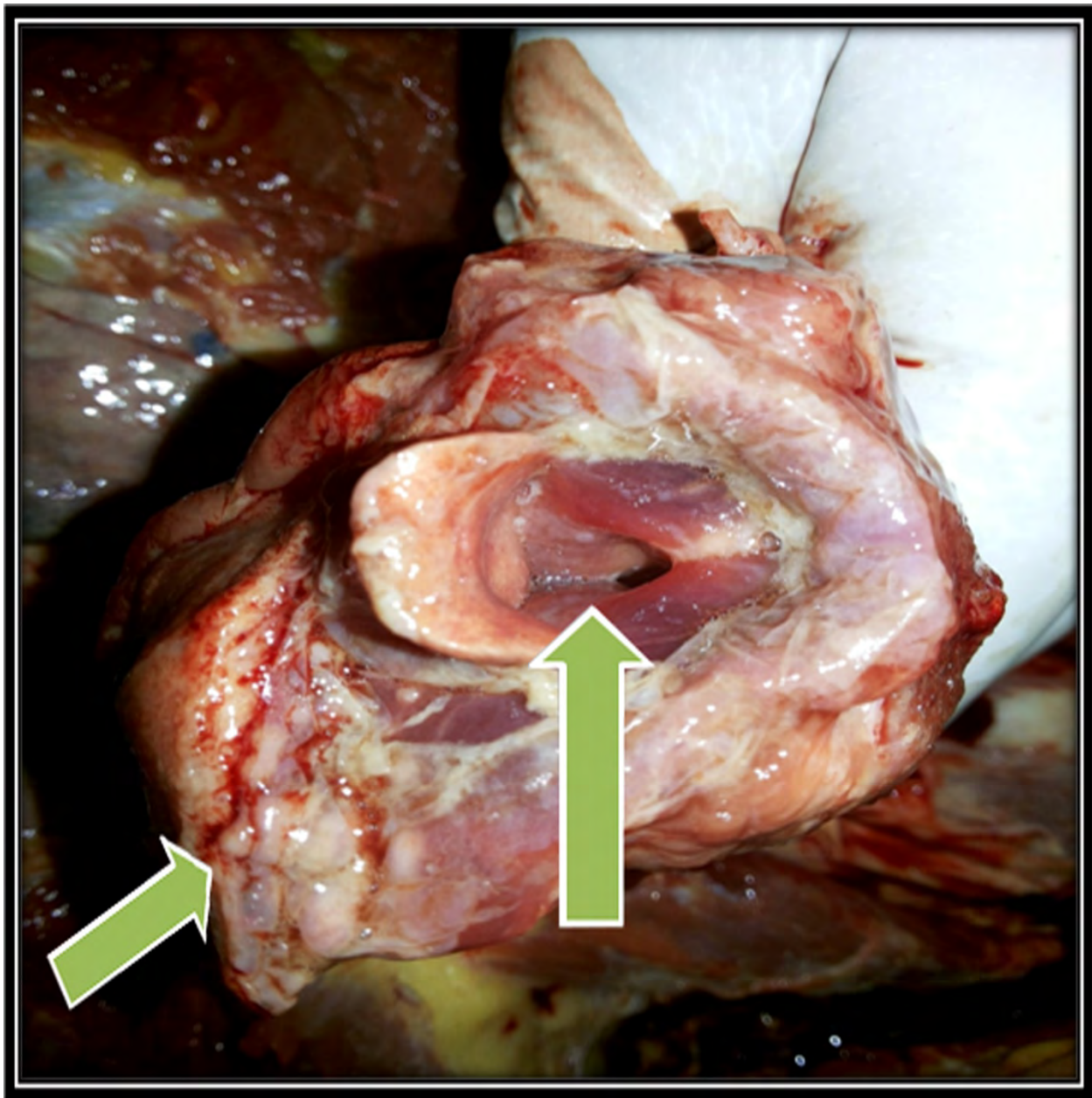
*Figure 9 - Yellowish discoloration with excoriation of lower lips with chalky white teeth in case 2.*

The base of the tongue, epiglottis, laryngeal orifice, and the entire pharyngo-esophageal junction appeared edematous with greyish-white discoloration. [Figure-10, 11, 12,13].

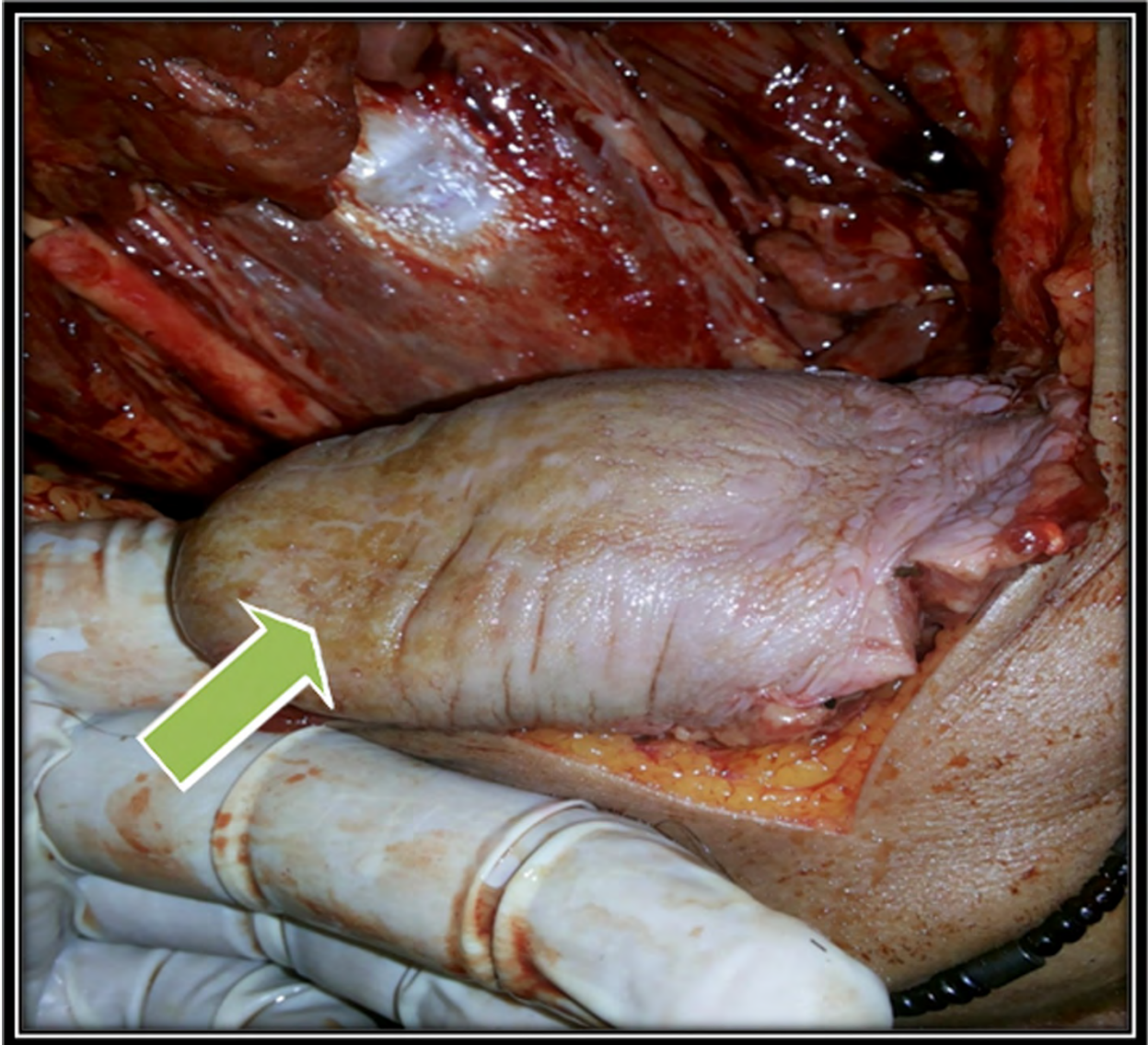


*Figure 10 - Swelling and grayish white excoriation around the laryngeal inlet with narrowing of the laryngeal inlet in case 2.*

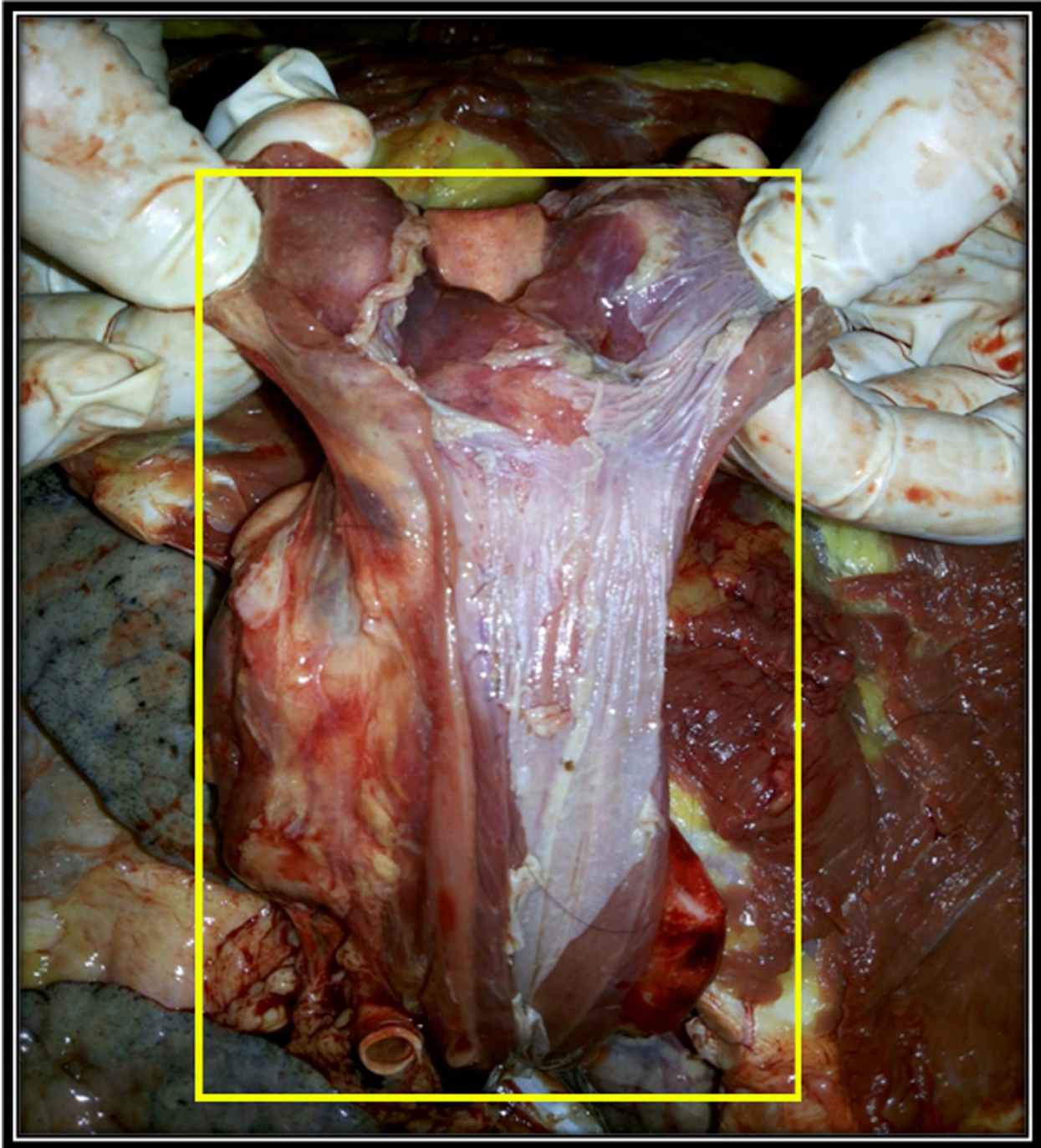
The mucosal lining of the esophagus appeared sloughed off with a greyish-yellow discoloration. The laryngeal inlet was significantly narrowed [Figure-11] because of the edema in the surrounding tissues.



*Figure 11 - Swelling and excoriation of the tongue base with narrowing of the laryngeal inlet in case 2.*

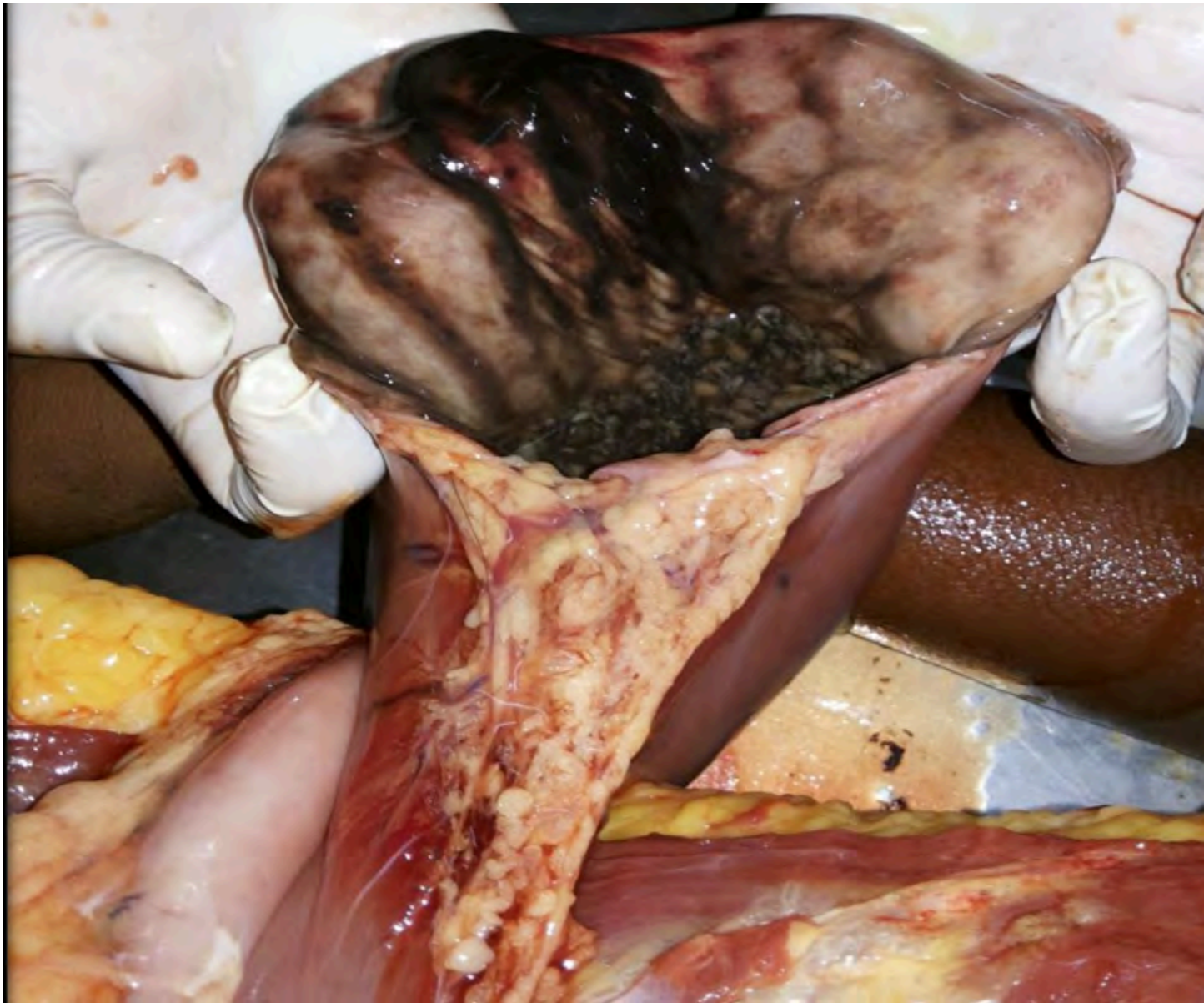

*Figure 12 - Yellowish discoloration and excoriation of the tongue in case 2*



**Figure 13-** *Greyish white excoriation seen throughout the wall of lumen of esophagus in case 2*

The gastric mucosa was congested proximally and discolored black. The gastric content in the stomach appeared to be partially digested rice 150gm along with the liquid, which had a pungent aromatic odor similar to vinegar. [Figure-14]



**Figure14** - Blackish discoloration of the stomach wall and contents of the stomach in case2

The small intestines contained some partially digested food, and the contents were identical to that found in the stomach with an identical smell. The small intestinal mucosa was healthy-looking. Toxicological analysis of the viscera and the blood reported acetic acid and paracetamol. Quantitative estimation of both the substances was not done. On verbal autopsy, the family members confirmed that the patient had consumed acetaminophen in therapeutic doses for headaches. The fact that the patient died within hours of the onset of symptoms of choking sensation in the neck, absence of any tablets or remnants in the stomach and intestines with no circumstantial evidence of paracetamol overdose as noted by police, paracetamol poisoning was not considered to be significant. The history showed that the patient died within 4 hours of ingestion of vinegar before receiving any medical help. In this case, the cause of death was opined as due to asphyxia resulting from laryngeal edema as a result of vinegar ingestion. The manner of death was determined as suicide.

Verbal autopsy findings suggested that both the deceased had made confessions in front of family members that they had deliberately consumed vinegar (150 ml in the first case and 100 ml in the second case). The police seized empty bottles of commercially available vinegar (5% acetic acid) as material evidence from the crime scenes.

**Discussion-** Acetic acid is a common chemical component of many household products like vinegar and rubber acid. It finds its use in the rubber and hat industry, food preservation, dyeing, and rayon industry. Apart from this, there are many medicinal uses of acetic acid. While lower concentrations of 2–6% are more commonly used as tabletop condiment (vinegar), much stronger solutions are used as food preservatives and cleaning solutions.<sup>5</sup> Thus, it is easily accessible in large amounts to the suicide attempters. Literature across the world has reported misuse of acetic acid in accidental, suicidal<sup>6,7</sup> and homicidal poisonings and for inducing abortion.<sup>4</sup> Acetic acid, in

the concentration of 80%, is being readily used in Eastern European countries and Russia, where many cases of its poisoning have been reported. In India, its use as vinegar (5-10% concentration of acetic acid) is a condiment used in daily cooking.

Acid ingestion causes eschar formation in the esophagus and mucosal damage in the stomach. Damage to the small bowel is uncommon after corrosive ingestion as reflex pyloric spasm limits the passage of the substance into the small intestine.<sup>8</sup> However, in the first case of the present report, the small intestinal wall was found involved, though in a patchy manner, which suggested a larger amount of acid ingestion. This fact correlated well with verbal autopsy records. Protective pyloric spasm is lost in patients with a history of prior gastric surgeries like pyloroplasty or gastric bypass, which can result in similar damage to the small bowel.<sup>9</sup> The deceased did not have any such surgical history. Ingestions leading to sudden upper airway obstruction have also been reported by Tibballs *et al.*, 2006.<sup>10</sup> Autopsy in the second case showed laryngeal edema and narrowing of the airway as well as death in a short period suggests asphyxia as the mode of death.

Brusin and Krayeva<sup>7</sup> examined 400 cases of highly concentrated acetic acid (70%) poisoning in the only large-scale case review published in the literature. Exposure to concentrations as low as 10% was reported to cause permanent damage to eyesight in animal studies,<sup>11</sup> while concentrations exceeding 12% result in local corrosive action and various systemic effects. In men, the most frequently observed complications of acetic acid included hemolysis (55%), renal failure (35%) and pneumonia (27%).<sup>7</sup> The acid is absorbed into the systemic circulation, and erythrocytes are the first to be affected, resulting in intravascular hemolysis and hemoglobinuria. This is followed by acute renal and hepatic failure, coagulopathy, and shock. Acute renal failure results from direct toxic action of acetic acid to renal tubules or indirect damage by hemoglobinuria. A combination

of both together with concurrent hypotension can cause further damage to the renal parenchyma. Mortality with acetic acid can be up to 20%, even in the best care conditions.<sup>12</sup>

In the treatment of a patient with acetic acid ingestion, along with rapid resuscitation measures supporting 'ABCD,' simultaneous early grading of the severity of the injury is necessary. Traditionally, grading the gastrointestinal mucosal injury by the Zargar scale [Table-1] is used to predict the need for surgical intervention and long term morbidity and mortality.<sup>13</sup>

**Table-1: Zargar's classification and its corresponding endoscopic findings<sup>21</sup>**

<b>Zargar classification</b>	<b>Description</b>
Grade 0	Normal mucosa
Grade I	Edema and erythema of the mucosa
Grade IIA	Haemorrhage, erosions, blisters, superficial ulcers
Grade IIB	Circumferential lesions
Grade III A	Focal deep grey or brownish black ulcers
Grade IIIB	Extensive deep grey or brownish black ulcers
Grade IV	Perforation

Most experts agree that the timing of endoscopy should be within the first several hours after ingestion. The drawbacks of endoscopy are – a. It is not readily available in resource poor settings b. It can not accurately determine the depth of necrosis c. Endoscopic grading is observer dependent. d. Upper gastrointestinal endoscopy is best avoided between 5 days and 15 days after ingestion because of the risk of iatrogenic perforation. Thus, contrast-enhanced computed

tomography (CECT) based grading of corrosive injuries has been proposed to address these bottlenecks.<sup>2,14</sup> Endoscopy should be preferred over CECT only in cases of renal failure, contrast allergy, pediatric population, and in cases where the CECT findings are not conclusive.<sup>2,15,16</sup>

Emergency surgery should be undertaken in patients having transmural necrosis of the gastrointestinal tract on endoscopy with an aim to remove all the necrotic tissue.<sup>17</sup> The other essential modalities that can be adopted for treatment are- high dose proton pump inhibitors to improve esophageal healing after ingestion of caustic material,<sup>2</sup> early plasmapheresis,<sup>18</sup> hemodialysis<sup>19</sup> and early feeding by enteral route.<sup>20</sup> Patients should be covered under antibiotics as per local practices. As per the study by Brusin *et al.*, pneumonia, kidney damage, Zargar Grade IIIa, IIIb, IV injury, and the large volume of acid ingestion as per verbal autopsy are the most ominous signs.<sup>7</sup>

**Conclusions-** Acid ingestion in the form of acetic acid (in varying concentrations) has been reported in Russia and Europe and is attributed to its easy availability in households for food preservation. However, the increasing incidence of suicidal poisoning from vinegar ingestion is attributed to the unregulated cheese curd industry. The present case report is the first such in eastern India among this group. This also calls for strict policy implementation for the preservation and accountability of these chemicals to prevent such mishaps in the future. The amount of the ingested corrosive and the grading of the mucosal necrosis determines the prognosis of the acetic acid ingestion. CECT based grading methods instead of endoscopy based methods need to be done unless the patient presents with complications.

Vinegar (5% acetic acid) is a tabletop condiment and is easily available in households. Accidental intake of vinegar is not uncommon, but its pungent odor and repugnant taste limits its use, thus resulting in milder injuries. Its use in higher concentrations is implicated in suicidal and homicidal poisonings particularly in Russia and Eastern Europe. The present study reports two cases of suicidal poisoning and deaths following deliberate self-ingestion of vinegar in a setting of easy availability of this chemical in huge quantities for occupational use.

### **List of abbreviations-**

ABCD-Airway breathing circulation disability.

CECT- Contrast Enhanced Computerized Tomography

**Acknowledgements-** We acknowledge the staffs of SCB Medical College, Cuttack Odisha for their help during this work

### **References**

1. Mowry JB., Spyker DA, Cantilena LR, McMillan N (Jr), Ford M. 2013 Annual report of the American association of poison control centers' national poison data system (NPDS): 31st annual report. Clin Toxicol (Phila).2014; 52(10),1032–1283. PMID: 25559822
2. Chirica M, Bonavina L, Kelly MD, Sarfati E, Cattan P. Caustic ingestion. Lancet. 2017; 389 (10083): 2041–2052. PMID: 28045663.
3. Lakshmi CP, Vijayahari R, Kate V, Ananthakrishnan N. A hospital-based epidemiological study of corrosive alimentary injuries with particular reference to the Indian experience. Natl Med J India. 2013;26(1):31–6.PMID: 24066992

4. Shields L, Rolf C, Hunsaker J. Sudden death due to forced ingestion of vinegar. *Forensic Science International*, 2016; 266: e23-e26. PMID: 27421692
5. Johnston C S, Gaas C A. Vinegar: medicinal uses and antiglycemic effect. *Med Gen Med : Medscape general medicine*.2006; 8(2): 61. PMC1785201
6. Bunyatov M O, Afandiyev I N. Acetic acid is the main reason of hospital mortality from acute exogenous intoxications in Azerbaijan. *Azerbaijan Medical Journal*. 2016; (2), 88-94.
7. Brusin KM, Krayeva YV. Highly Concentrated Acetic Acid Poisoning: 400 Cases Reviewed. *Asia Pacific Journal of Medical Toxicology*. 2012; 1, 3-9. DOI: 10.22038/APJMT.2012.19
8. Ananthkrishnan N, Parthasarathy G, Kate V. Acute Corrosive Injuries of the Stomach: A Single Unit Experience of Thirty Years. *ISRN Gastroenterology*. 2011;2011 Article ID 914013. doi:10.5402/2011/914013
9. Pankaja S, Valooran G, Das S, Suvasini L, Aravind R, Kate V, et al. Isolated full thickness jejunal necrosis following sulphuric acid cocktail ingestion—a clinical case report—isolated corrosive jejunal necrosis. *Surg Sci*.2011; 2:338–40. DOI: 10.4236/ss.2011.26072
10. Tibballs J, Cathie R, Buist M, Shimizu K, Stokes K, & Millar J. Upper Airway Obstruction Caused by Ingestion of Concentrated Acetic Acid. *Anaesthesia And Intensive Care* 2006; 34(3): 379-81. PMID: 16802496
11. Morales ML, Tesfaye W, Garcia-Parrilla MC, Casas JA, Troncoso AM. Evolution of the aroma profile of sherry wine vinegars during an experimental aging in wood. *J Agric Food Chem*. 2002; 50: 3173–8. PMID: 12009982

12. Ratcliffe A, Baker A, Smith D. Successful management of 70% acetic acid ingestion on the intensive care unit: A case report. *J Intensive Care Soc* 2018; 19(1):56-60.
13. Zargar SA, Kochhar R, Mehta S, Mehta SK. The role of fiberoptic endoscopy in the management of corrosive ingestion and modified endoscopic classification of burns. *Gastrointest Endosc.*1991; **37**(2):165–9. PMID: 2032601
14. Bruzzi M, Chirica M, Resche-Rigon M, Corte H, Voron T, Sarfati E, Zagdanski A M, Cattan P. Emergency Computed Tomography Predicts Caustic Esophageal Stricture Formation. *Annals of surgery* 2019; 270(1): 109–14. PMID: 29533267
15. Chirica M, Kelly MD, Siboni S, Aiolfi A, Riva CG, Asti E, et al. Esophageal emergencies: WSES guidelines. *World J Emerg Surg* 2019; 14: 26. PMID: 31164915
16. Bonavina L, Chirica M, Skrobic O, Kluger Y, Andreollo NA, Contini S, et al. Foregut caustic injuries: results of the world society of emergency surgery consensus conference. *World J Emerg Surg.*2015; 10:44. PMID: 26413146
17. Kalayarasan R, Ananthkrishnan N, Kate V. Corrosive Ingestion. *Indian J Crit Care Med.* 2019 ; 23(Suppl 4): S282-S286. PMID: 32021005.
18. Tong G, Mak S, Wong P, Lo K, So S, Watt C, Wong A. Successful treatment of oral acetic acid poisoning with plasmapheresis. *Hong Kong Journal Of Nephrology* 2000; 2(2): 110-2. DOI: 10.1016/S1561-5413(09)60046-6
19. Silfen R, Vilan A, Wohl I, Leviav A. Mediterranean jellyfish (*Rhopilema nomadica*) sting. *Burns* 2003;**29**: 868–70. PMID: 14636769

20. Chibishev A, Markoski V, Smokovski I, Shikole E, Stevcevska A. Nutritional therapy in the treatment of acute corrosive intoxication in adults. *Materia socio-medica*, 2016; 28(1): 66–70.

PMID: 27047272

21. Zargar SA, Kochhar R, Mehta S, Mehta SK. The role of fiberoptic endoscopy in the management of corrosive ingestion and modified endoscopic classification of burns. *Gastrointest*

*Endosc.* 1991; **37**:165–169.